IJCSN International Journal of Computer Science and Network, Volume 6, Issue 2, April 2017
ISSN (Online) : 2277-5420
www.IJCSN.org
Impact Factor: 1.5

Brain Tumor Detection Using 3D Visualization

[1] Prachi Dhikale; [2] Madhuri Joshi

[1, 2] Department of Computer Science and Engineering, Jawaharlal Nehru Engineering College, Aurangabad, M. S., India.

Abstract - A tumor is a development in the anomalous tissue which can be separated from the encompassing tissue by its structure. A tumor may prompt to growth, which is a noteworthy driving reason for death and in charge of passings around the world. Tumor rate is developing at a disturbing rate on the planet. Incredible learning and experience on radiology are required for exact tumor location in medicinal imaging. We propose a Visualization of 3d View of Detected Brain Tumor and Calculation of its Volume that can identify and confine brain tumor in attractive reverberation imaging. The proposed brain tumor identification and restriction structure contains four stages: image acquisition, pre-processing, edge recognition, and morphological operations. It additionally incorporate tumor location with examinations lastly 3D model is get of tumor recognized segment with its volume. Proposed technique built up a tumor recognition strategy utilizing three parameters; edge (E), gray (G), and threshold value (T) values. The technique proposed here concentrated the EGT parameters in a regulated square of info images. These component squares were contrasted and institutionalized parameters to recognize unusual events, e.g. image piece which contain tumor cells. The proposed technique demonstrates more accuracy among the others. Preparing time is less. This will help the doctors in dissecting the brain tumors precisely and proficiently. It is utilized to fragment the mind tumor from 2D images and after that changing over it into 3D for further model investigation and volume calculation.

Keywords - *Brain Tumor, Edge Detection, MRI , Segmentation, Thresholding.*

1. Introduction

Tumor is a standout amongst the most widely recognized brain ailments, so its finding and treatment have a fundamental significance for the people experiencing brain tumor on the planet. Then again, as of late, improvements in therapeutic imaging procedures permit us to utilize them in a few spaces of drug, for instance, PC helped pathologies finding, follow-up of these pathologies, surgical arranging, surgical direction, factual and time arrangement investigation. The examination and investigation of the brain is of awesome enthusiasm because of its potential for concentrate early development designs and morphologic changes in the disease procedure. Late reviews have shown the capability of a choice emotionally supportive network for recognizing tumors in therapeutic images, giving radiologists a moment combine of profoundly prepared eyes. It gives specialists access to extra data show in images that have qualities by and large acknowledged to be related with disease, groups of splendid recognizes that are suggestive of sores, examples suggestive of tissue masses or bends, and stamp districts that have the attributes of sores or tumors. Numerous sort of test are utilized to identify brain tumor, for example, MRI, Computed Tomography (CT) sweep, Biopsy and some more. Among the whole test MRI has extraordinary potential for order of tumor. X-ray, in examination with other symptomatic imaging modalities, for example, electronic tomography, gives better difference and determination than various brain tissues. Magnetic Resonance Imaging (MRI) strategies are as yet creating, and late endeavors have been coordinated essentially at enhancing image quality and speed of securing. X-ray gives non-intrusive, fantastic images of neuro-life systems and illness forms. Through its capacity to distinguish differentiate in the thickness of delicate tissues, MRI is appropriate to screen and assess brain tumors as they create and react or, by and large, neglect to react to treatment. There are many groupings that can be utilized on MRI and the distinctive successions frequently give diverse difference between tissues so the most suitable arrangement ought to be picked by ailment and what the clinicians need to recognize[4][9].

The paper is sorted out in a few segments: In the principal segment, a short audit about brain tumor. In the second segment, we talked about the Objectives. Procedure of the proposed framework is talked about in third area. Dataset are talked about in fourth area. In the last area we talked about experimentation and results.

2. Objectives

The first aim of this work is to develop a framework for a robust and accurate segmentation of a large class of brain tumors in MR images. Most existing strategies are area based. They have a few focal points, however line and edge data in PC vision frameworks are additionally imperative. The proposed strategy tries to join district and edge data, in this way exploiting both methodologies while wiping out their disadvantages. 3D differentiate improved T1-weighted and FLAIR images are the contributions to play out a programmed division of the strong piece of tumor and the potential related edema and corruption .We first fragment the brain to evacuate non-brain information. Nonetheless, in neurotic cases, standard division techniques flop, specifically when the tumor is found near the brain surface. Along these lines we propose an enhanced division technique, depending on the estimated symmetry plane. At that point we created two new and unique techniques to identify and at first portion mind tumors. The first is a fluffy grouping strategy which consolidates participation, ordinariness and neighborhood data. The second one depends on a symmetry-based histogram investigation. The rough sagittal symmetry plane is initially processed, and the tumor is then separated by contrasting the histograms of the two cerebral halves of the globe. To refine the underlying division, which is not sufficiently precise, we utilize edge data. A deformable model obliged by spatial relations is connected for this reason. Volume of extreme square of image is additionally figured.

3. Proposed System

3.1 Proposed Methodology

The algorithm has two phases, first is preprocessing of given MRI Image and second is Tumor Detection and 3D representation in the wake of figuring volume of identified part of tumor. At that point perform morphological operations on them.

Algorithm steps are as follows:-

i) Give MRI images as input (this is images of tumor).
ii) Convert this image into gray scale.
iii) Compute threshold segmentation.
iv) Calculate the boundaries using edge detection sobel algorithm is used.
v) Tumor Detection.
vi) Tumor Comparisons
vii) 2D visualization of Tumor
xii) 3D visualization of tumor and volume calculation.
xi) Finally we will get a final output a tumor region.

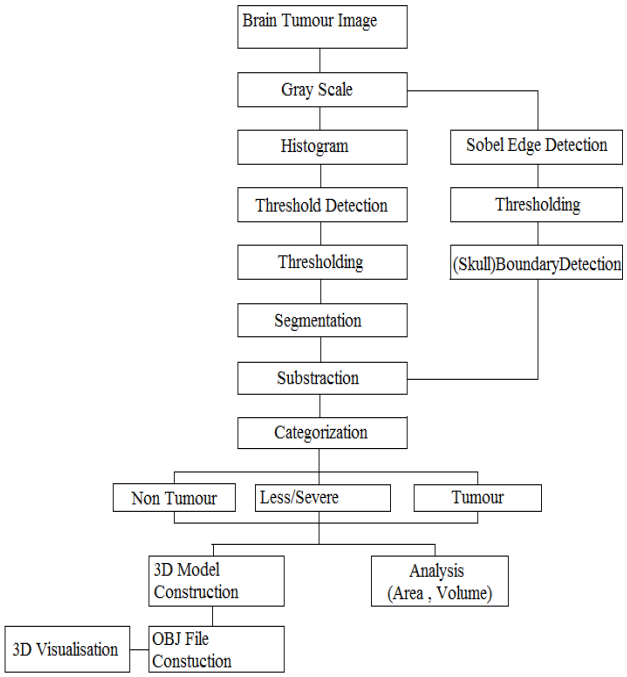

Figure 1. Proposed Method

3.1.1. Preprocessing of tumor image:

Preprocessing incorporates some more operations like dark scaling of image. Threshoulding and edge identification of image. The aftereffect of preprocessing stage is sans commotion, image is standardized with the goal that it can continue for further tumor discovery stage.

A) **Gray-scaling of tumor image:**

In image processing, a grayscale or greyscale advanced image is a image in which the estimation of every pixel is a solitary example, that is, it conveys just power data. Images of this sort, otherwise called high contrast, are made only out of shades of dim, changing from dark at the weakest force to white at the most grounded. Grayscale pictures are particular from high contrast images, which with regards to PC imaging are images with just the two hues, high contrast (likewise calle double pictures). Grayscale images have many shades of dark in the middle. Grayscale images are additionally called monochromatic, signifying the nonattendance of any chromatic variety (i.e.one shading). Grayscale images are frequently the consequence of measuring the force of

light at every pixel in a solitary band of the electromagnetic range (e.g. infrared, unmistakable light, bright, and so forth.), and in such cases they are monochromatic legitimate when just a given recurrence is caught. Be that as it may, likewise they can be orchestrated from a full shading image. The force of a pixel is communicated inside a given range between a base and a most extreme, comprehensive. This range is spoken to in a theoretical route as a range from 0 (add up to nonappearance, dark) and 1 (add up to nearness, white) with any fragmentary values in the middle.

B) Threshoulding of tumor image:

Threshoulding is the least complex strategy for image division. From a grayscale image. Threshoulding can be utilized to make double images i.e. image with just dark or white hues. It is normally utilized for highlight extraction where required components of image are changed over to white and everything else to dark. (On the other hand the other way around). Threshoulding is the least difficult technique for image division. From a grayscale image, Threshoulding can be utilized to make parallel images. A mid the threshoulding procedure, singular pixels in a image are set apart as "question" pixels if their esteem is more noteworthy than some limit esteem (expecting a protest be brighter than the foundation) and as "foundation" pixels generally. This tradition is known as limit above. Variations incorporate edge underneath, which is inverse of edge above; edge inside, where a pixel is marked "objectss" if its value is between two limits; and edge outside, which is the inverse of edge inside .Typically, a protest pixel is given an value of"1" while a foundation pixel is given an estimation of "0." Finally, a double image is made by shading every pixel white or dark, contingent upon a pixel's names.

C) Edge Detection:

For the recognition of edges strategy utilized is sobel. Edge discovery alludes to the way toward recognizing and finding sharp discontinuities in a image. The discontinuities are sudden changes in pixel power which describe limits of articles in a scene. Traditional strategies for edge identification include convolving the picture with an administrator (a 2-D channel), which is built to be touchy to expansive angles in the image while returning estimations of zero in uniform areas. There is an amazingly substantial number of edge discovery administrators accessible, each intended to be delicate to specific sorts of edges.

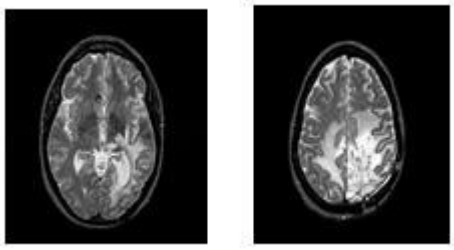

Figure 2. Test tumor pictures

3.1.2. Tumor Detection:

In this stage to stack any tumor images and tumor identification is finished.

A) Feature Block: In most restorative images, the structures of intrigue, for example, tumors, injuries and veins, possess a rate that is regularly well beneath 10% of the aggregate number of pixels. Conventional medicinal imaging includes outwardly contrasting images one next to the other with recognize contrasts from ordinary oremergence of changes with time. Recognizing minute contrasts between two images however can be about inconceivable. For the examination of such little tissues or structures, we concocted a piece framework that partitions the locale f intrigue (ROI), which is profoundly reliant on imaging modalities, into square size (B). A piece (B) is meant as a piece of the entire image (ROI), isolated equitably by a variable of eight, as appeared in Fig. 3.This directed square is further isolated into tumor obstructs that are arranged from low-thickness tumor pieces to high-thickness tumor squares. The distinctive levels of the EGT estimation of the element square are spoken to as various hues, and the shading code is demonstrated as follows:

a) Severe Block:-Red Color
b) Less Severe Block:-Yellow Color

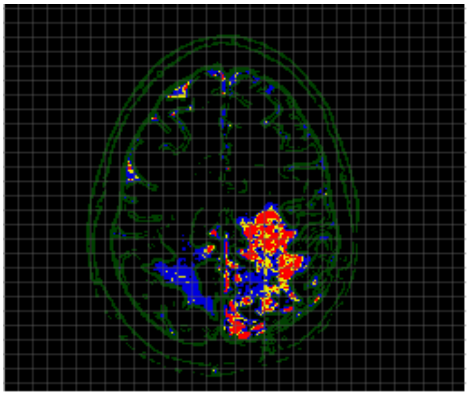

Figure 3. Tumor Detection Image

B). Multiparameter :

Late advances in medicinal image investigation frequently incorporate procedures for a picture to be portioned as far as a couple of parameters and into littler sizes or districts, to address the diverse parts of breaking down pictures into anatomically and pathologically important areas. Ordering areas utilizing their multiparameter values makes the investigation of the districts of physiological and obsessive premium less demanding and more determinable. Here, multiparameter highlights allude to the accompanying three particular qualities for the edges (E), grey value (G), and Threshold Value (T) of the pixels.

Gray-Scale: In this method, the grey value parameter (G) for each piece is figured as beneath – Read singular pixel shading value (24-bit). – Split the shading an incentive into individual R, G and B 8-bit values.
Compute the grayscale part (8-bit) for given R, G and B pixels utilizing a change equation Create a 24-bit pixel value from 8-bit grayscale esteem. Store the new incentive at same area in yield image. Navigate Through Entire Image for(y=0;y<height;y++) { for(x=0;x<width;x++) { pix = input[y][x];
Remove 8-bit R, G and B values from 24-bit Color Value b = pix and 0xff; g = (pix >> 8) and 0xff; r = (pix >> 16) and 0xff;
E.g. Expect PIXEL value is 0x435A56 where 0x43 is red, 0x5A is green and 0x56 is blue part. Presently to separate blue we can utilize the LOGICAL AND administrator to veil or channel the blue segment from the rest. Since AND'ing with 1 has no effect where as AND'ing with 0 will constrain the bit to 0.
435A56
What's more, 0000FF
- -
0x000056 - blue isolated
For Green we might first right move the pixel value by 8 bits so that green part is presently at LSB position. And after that rehash the concealing procedure.
435A56 >> 8 = 435A
0x435A
AND 0x00FF
- -
0x005A - green isolated
Essentially we might right move by 16 bits so that red part will be at the LSB position and afterward do the covering. As certain grayscale part
gs = (r + g + b)/3;

There are different approaches to change over shading qualities to grayscale. Any one can be utilized relying upon the client's needs.

RGB Averaging Formula
gs = (r+g+b)/3;
Here normal of every one of the three hues is computed and spared in yield image.
Above equation can likewise be composed as
gs = r * 0.33 + g * 0.33 + b * 0.33;
i.e. 33% of all hues is utilized to create last 100% grayscale segment.

Threshoulding: In this Image division the image is partitioned into numerous parts. By doing this we can distinguish objects or other related data in the given advanced image. We can state this likewise alludes to the apportioning of a image into different arrangements of pixels (that share some basic attributes, for example, shading or force).

a) First figure the part of continue image which is distinguished. (small esteem)
b) Figure limit value. What's more, allot th=sumall (edge value).
c) Discover greatest and least force value. Tmin and Tmax
d)Range r=Tmax-Tmin,also find range1,range2 and range3. range1 = (int) ((maxCol - minCol) / 4.0) + minCol; range2 = (int) ((maxCol - minCol) / 2.0) + minCol; range3 = (int) ((maxCol - minCol) * 3.0 / 4) + minCol; e)Tsevere=(R3/4)+Tmin , T_less_severe=(R(1/2))+Tmin.
f) Calculate blockwise score. If blockscore greater then redcount increase otherwise yellow count increase.
g) Fill severe block with red color and less severe block with yellow color.
i)Display the result of count of block having severe and less
severe block.

Edge Detection:

Sobel Edge discovery technique is utilized Sobel Operator as beneath: The administrator comprises of a couple of 3×3 convolution parts as appeared in Figure 1. One bit is essentially the other pivoted by 90°[5].

-1	0	+1
-2	0	+2
-1	0	+1

Gx

+1	+2	+1
0	0	0
-1	-2	-1

Gy

These portions are intended to react maximally to edges running vertically and evenly in respect to the pixel framework, one bit for each of the two opposite introductions. The bits can be connected independently to the info image, to deliver isolate estimations of the slope part in every introduction (call these Gx and Gy). These can then be consolidated together to locate the total greatness of the slope at each point and the introduction of that angle. The angle extent is given by:

$$|G| = \sqrt{Gx2 + Gy2}$$

Intelligent 3D perspective of 25 images is produced. What's more, shows ordinarily an estimated extent is registered utilizing:

$$|G| = |Gx| + |Gy|$$

3.1.3. Tumor Comparisons:

The goal of this stage is to extricate the elements of the test image that will be contrasted with the components of other tumor image for check reason[10].

3.1.4. 2D visualization of tumor:

In this two dimensional view of image of tumor is generated.

3.1.5. 3D visualization of tumor:

Interactive 3D view of images are generated. And shows the severe and less severe block from the images.

4. Dataset

In this study, we have obtained some MRI scan images of a person from Apex hospital of Aurangabad, Maharashtra, India.. Dimensions of tumor images are 256x256. The method is tested on Microsoft windows XP (Professional), Windows 7, Windows 8.1 and Windows 10. In order to implement this 3D brain tumors and internal brain structures JAVA program is used. This program could speed up the development of this system because it has facilities to draw forms and to add library easily.

5. Results and Discussions

The dataset contains 30 tumor images and 25 non tumor images. The identified images from the tumor class are 28 while the identified images from non tumor class are 22. According to the developed algorithm 26 out of 00 tumor class image were correctly detected while 16 out of 20 non tumor class images were accurately identified. Here is the summary of my findings in tabular form.

Figure 4 shows tumor detection on single slice. Figure 5 represents tumor comparison. Figure 6 shows the construction of 3D model and the GUI design of application to show processing of 3D Model is shown in figure 7.

Table no 1: Analysis

Dataset Name	Total	Correct
Tumor Image	28	25
Non Tumor Image	22	20

Table no 2: Precision and Sensitivity

Image	Precision	Sensitivity	Accuracy
Tumor	0.89	0.83	83%
Non Tumor	0.95	0.8	80%

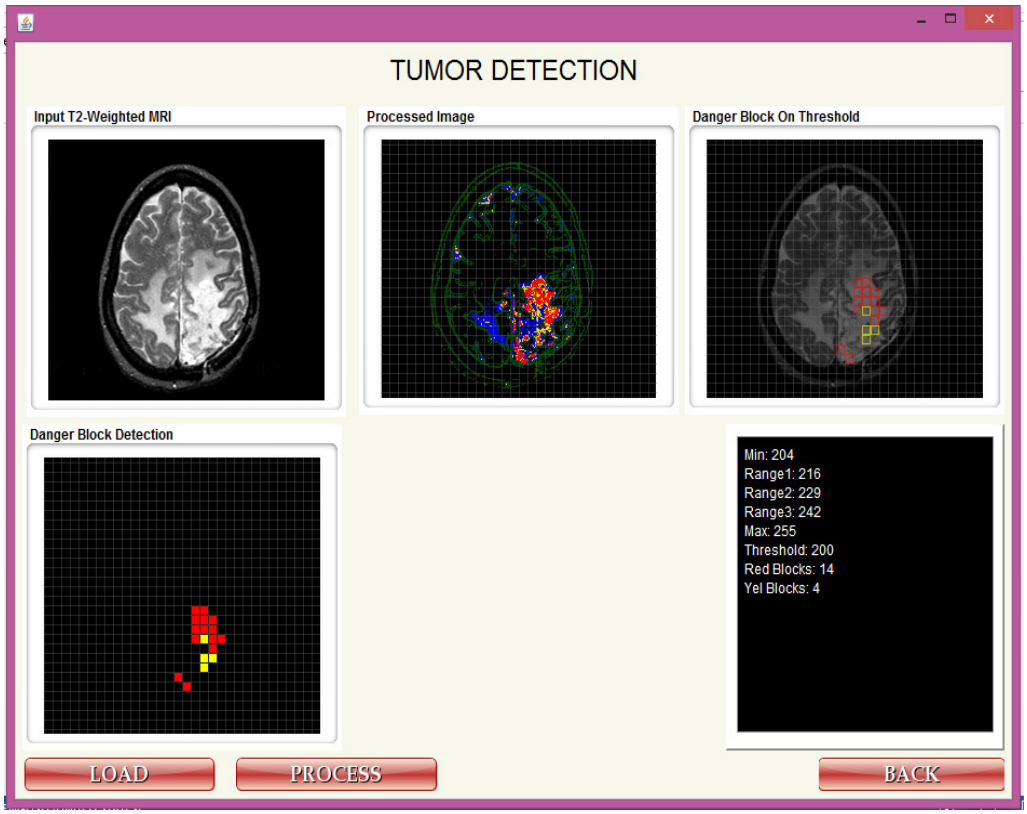

Figure 4.Detection results on single slice.

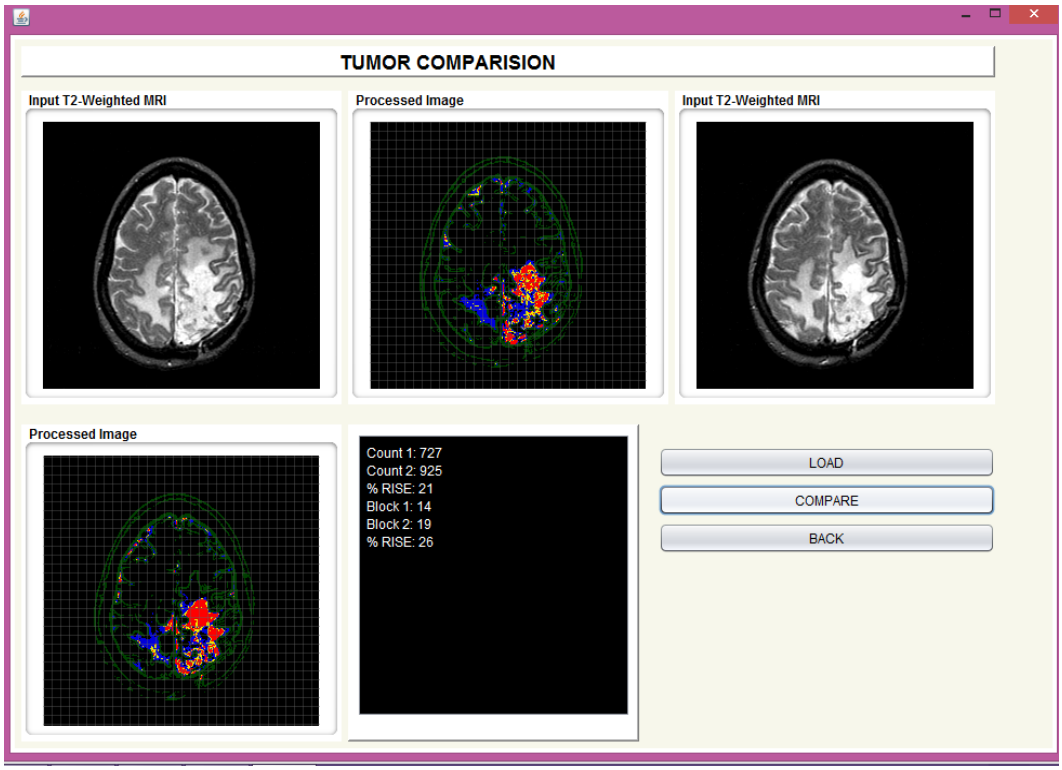

Figure 5.Detection Result on two slice.

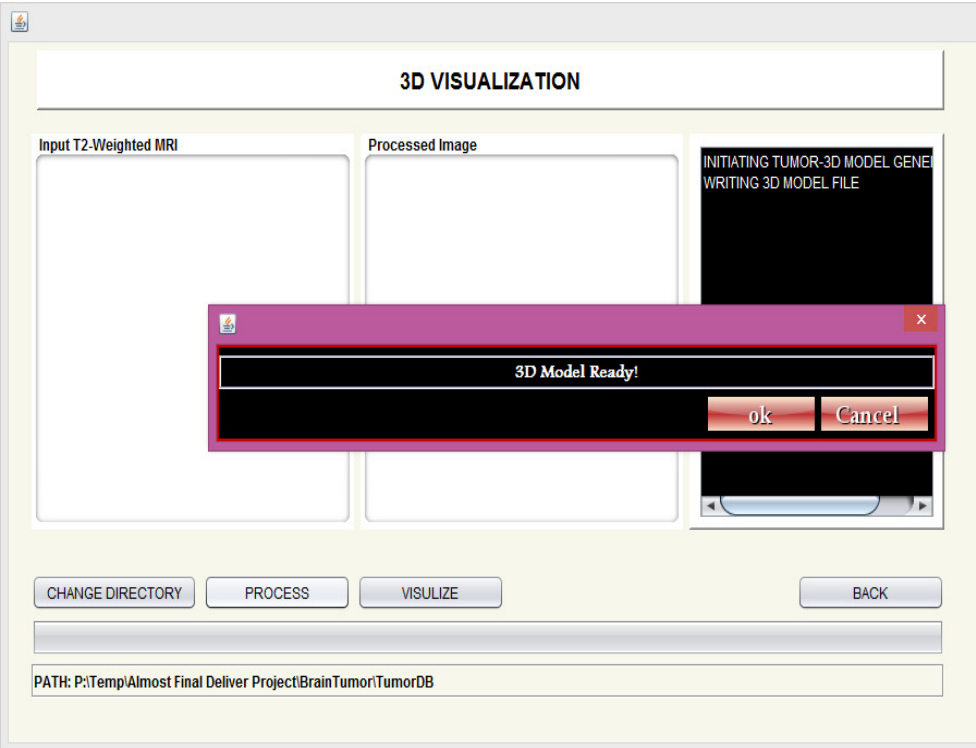

Figure 6. Contruct 3D Model.

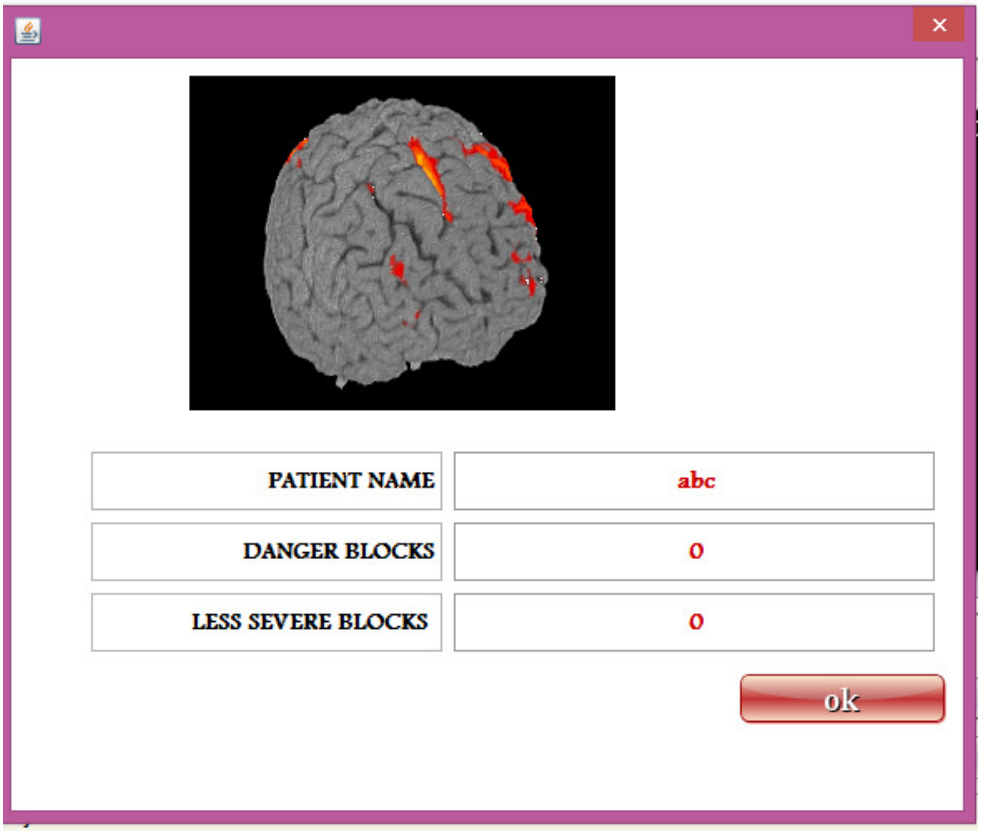

Figure 7. GUI design of application to show processing of 3D Model.

6. Conclusion

In this paper, we presented a thoughtfully basic characterization strategy utilizing multiparameter highlights on regulated square to computationally order mind pictures. Our decision is that the proposed technique is viably fit for recognizing tumor ranges in T2-weighted restorative cerebrum pictures taken under various clinical conditions and specialized conditions, which could demonstrate high deviations that obviously showed irregularities in territories with mind malady. After which the 3D volume portrayal of the tumor can be gotten inside few moments as said above. This will spare a ton of time of the specialists and radiologist giving a much current strategy to cerebrum tumor surgery. As the future work, the legitimacy of technique can be seen by applying to more instances of same sort and in addition on different sorts of tumor. Keeping in mind the end goal to coordinate the consequences of volume with the first information we need such cases in which the entire tumor is sent for biopsy. The 3D examination and volume counts should be possible by whatever other programming, for example, SPM and MATLAB. The outcomes can be looked at. This will permit blunder figurings to be finished. By 3D displaying of various sorts of tumors we can see the likenesses and contrasts between them with respect to their shapes and structures which will be useful for the doctors. This should be possible with top to bottom investigation of various instances of tumor which thus help the restorative experts in ordering the tumors sorts on the premise of their volume.

References

[1] Ed-Edily Mohd. Azhari1, Muhd. Mudzakkir Mohd. Hatta1, Zaw Zaw Htike1and Shoon Lei Win2, “Brain Tumor Detection And Localization In Magnetic Resonance Imaging”, International Journal of Information Technology Convergence and Services (IJITCS) Vol.4, No.1, February 2014.

[2] Sudipta Roy, Atanu Saha and Prof. Samir K Bandyopadhyay,”Brain Tumor Segmentation and Quantification from MRI of brian”Journal of global Research in Computer Science, Volume 2, N0. 4, April 2011.

[3] Sonam S. Gavhande, S.B.Jadhav,”Image Segmentation and Identification of Brain Tumor from MRI Image”, International Research Journal of Engineering and Technology (IRJET) in Volume: 02 Issue: 02 | May2015.

[4] Ayesha Amir Siddiqi, Attaullah Khawaja Mashal Tariq, Department of Electronics N.E.D.”3D volume representation of brain tumor using Image Processing”, 2011 IEEE International Conference on Signal and Image Processing Applications (ICSIPA), March 2011 .

[5] Mr. Shital S. Agrawal, Prof. Dr. S. R. Gupta,” Detection of Brain Tumor Using Different Edge Detection Algorithm”, International Journal of Emerging Research in Management &Technology, in Research Article April 2014.

[6] T. Logeswari and M. Karnan,” An improved implementation of brain tumor detection using segmentation based on soft computing”,in Journal of Cancer Research and Experimental Oncology Vol. 2(1) pp. 006-014, March, 2010.

[7] Narkhede Sachin G “Brain Tumor Detection Based On Mathematical Analysis and Symmetry Information” Int. Journal of Engineering Research and Applications, Vol. 4, Issue 2(Version 1), pp.231-235 , February 2014.

[8] Mangipudi Partha Sarathi, Mohammed Ahmed Ansari, Vaclav Uher, Radim Burget, and Malay Kishore Dutta,” Automated Brain Tumor Segmentation using Novel Feature Point Detector and Seeded Region Growing”, in 2013 IEEE.

[9] A.R.Kavitha,Dept of IT, Dr.C.Chellamuthu Department of EEE, and Ms.Kavin Rupa,Department of CSE,” An Efficient Approach for Brain Tumour Detection Based on Modified Region Growing and Neural Network in MRI Images” 2012 International Conference on Computing, Electronics and Electrical Technologies [ICCEET].

[10] Geetika Gupta, Rupinder Kaur, Arun Bansal, Munish Bansal,” Analysis and Comparison of Brain Tumor Detection and Extraction Techniques from MRI Images”, International Journal of Advanced Research in Electrical,Electronics and Instrumentation Engineering(An ISO 3297: 2007 Certified Organization) Vol. 3, Issue 11, November 2014.