IJCSN International Journal of Computer Science and Network, May 2014
ISSN (Online) : 2277-5420
www.IJCSN.org

Conference Proceeding – RDFCORDGE - 2014

A Review on Medical Imaging Techniques and Mammograms Analysis Techniques Used for Breast Cancer Detection

[1]Prachi Damodhar Shahare, [2]Ram Nivas Giri

[1]M. Tech 4TH Semester (CSE), Raipur Institute of Technology,
Raipur, India.

[2]Associate Professor, Department of CSE, Raipur Institute of Technology,
Raipur, India.

Abstract -- Breast Cancer is a complex disease characterized by many morphological, clinical and molecular features. Imaging technologies have improved breast cancer diagnosis, better survival rates and treatment by early detection of primary or metastatic masses, differentiating benign from malignant tumors and promoting intraoperative surgical guidance and post operative specimen evaluation. This paper is a review of the different medical imaging techniques used in the diagnosis of breast cancer. Also this review shows different methods used for analysing mammographic images. Mammographic analysis could provide radiologists a better understanding and provides proper diagnosis, if it is detected at an early stage, a better prediction which brings about a significant decrease in mortality.

Keywords – *Breast Cancer, Mammography, MRI, PET, Computed Tomography, Mammogram Analysis, Segmentation, Classification.*

1. Introduction

Cancer refers to the uncontrolled multiplication of a group of cells in particular location of the body. A group of rapidly dividing cells may form a lump, microcalcifications or architectural distortions which are usually referred to as tumors. Breast cancer is any form of malignant tumor which develops from breast cells. Breast cancer is one of most hazardous types of cancer among women.

In 2013, over 232,000 women will be newly diagnosed with breast cancer, and it is predicted that more than 39,000 women will die from this disease [1]. Breast analysis techniques have been improved over the last decade. An urgent need in breast cancer control today is to develop effective and affordable approaches for the early diagnosis, detection and treatment of breast cancer among women. However, there still are issues to be solved: developing new and better techniques of contrast enhancement, segmentation and classification (using advanced texture analysis for example). Selecting better criteria for performance evaluation is also needed. In this paper, we review different medical imaging techniques in second section which are mostly used for breast cancer detection. The third section is a review on the different techniques of mammograms analysis.

2. Medical Imaging Techniques

Most widely used medical imaging techniques used for diagnosis of breast cancer are as follows:

A) Computer-aided mammography
B) Computed tomography
C) Magnetic resonance imaging (MRI)
D) PET scan
E) Ultrasound imaging

A. Computer-aided Mammography

Mammography is the single most important technique in the investigation of breast cancer, which is most occurring malignancy in women. This technique can detect disease at an early stage when surgery is most effective. The explanation of screening mammograms is a repetitive task involving subtle signs, and suffers from a high rate of false and false positives. Computer-aided diagnosis (CAD) aims to increase the predictive value of the technique by pre-reading mammograms to indicate the locations of suspicious masses that are not normal, and analyze their characteristics [2]. Mammography can detect approximately 78% of invasive breast cancer and its sensitivity is as high as 98% in women over 50 years old with fatty breasts [4].

One of the major limitations of mammography is its low sensitivity in dense breasts. Another disadvantage of mammography is the exposure of patients to the X-ray ionizing radiation, which may induce cancerous cells. In addition, the mammography screening process is sometime uncomfortable because the breast has to be compressed between flat surfaces to improve image quality [4].

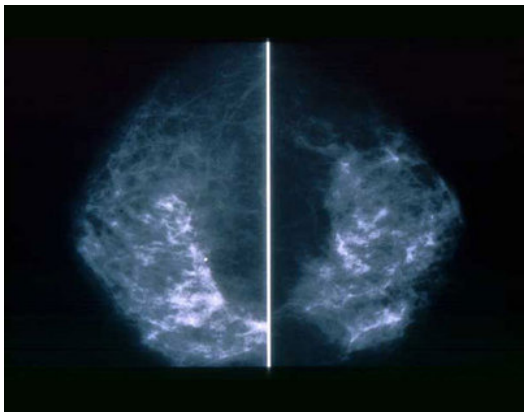

Fig.1. Mammogram showing no discrete abnormality

B. Computed Tomography

A CT scan (computerized tomography scan) is an X-ray technique that gives doctors information about the body's internal organs in 2-dimensional slices, or cross-sections. During a CT scan, patient lie on a moving table and pass through a doughnut-shaped machine that takes X-rays of the body from many different angles. An X-rays gets put together by a computer to created detailed pictures of the inside of the body.

Doctors might order CT scans to examine other parts of the body where breast cancer can spread to other parts of body such as the lungs, liver, lymph nodes, brain, spine and many more. Generally, CT scans wouldn't be needed if patient have an early-stage breast cancer.
One of its disadvantages is that before the test, patient need to have a contrast solution (dye) injected into arm or into a vein. Because the dye can affect the kidneys, doctor may perform kidney function tests before giving you the contrast solution [24].

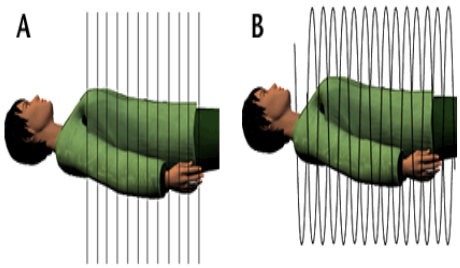

Fig.2 (A) Conventional CT scan,
(B) Spiral CT scan

C. Magnetic Resonance Imaging (MRI)

MRI (magnetic resonance imaging), is a technique that uses radio waves and magnets to produce detailed cross-sectional images of the inside of the body. X-rays are not used by MRI, so any radiation exposure does not involved by MRI. MRI of breast has a number of different uses in breast cancer detection. Breast MRI includes:

1) Screening of women with high-risk that means women known to be at higher than average risk for breast cancer may either because of a strong family history or a gene abnormality.
2) Generating more information about suspicious area
3) Monitoring for recurrence after treatment [24].

MRI may save patients from unnecessary surgery, there is a concern that findings on MRI may prompt unnecessary excess tissue removal or in some cases unnecessary mastectomy.

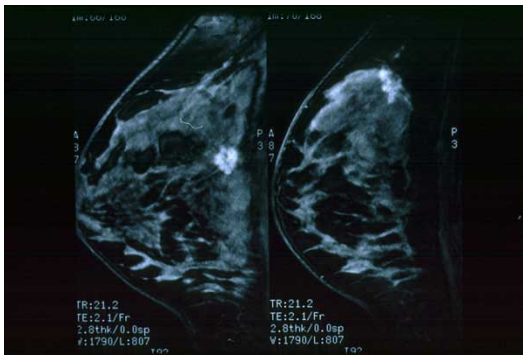

Fig. 3 MRI scan of the breast reveals two discrete areas of abnormality [24]

D. PET Scans

PET scans (Positron Emission Tomography) can detect cancer areas by obtaining images of the body's cells. Initially patients are injected with a substance made up of a small amount of radioactive material and sugar. Cancer cells have a habit to be more active than normal cells so as a result they absorb more of the radioactive sugar. The body is then scanned by a special camera to pick up any "highlighted" areas on a computer screen, which helps radiologists identify areas where cells are suspiciously active, finally which can indicate cancer.
Its disadvantage is that this scans are available in only very few places, and they are an expensive, complex tests that requires special expertise [24].

E. Ultrasound Imaging

Ultrasound is an imaging test that sends high-frequency sound waves through breast and converts them into images on a viewing screen of computer. The ultrasound technician uses a sound-emitting probe, which get placed on the breast to conduct the test of patient. There is no radiation involved in this technique. Doctor may recommend ultrasound before mammography to evaluate a palpable breast lump [24].

Recent studies [32] suggest a predictive value of almost 98% for detecting invasive lobular carcinoma when both mammography and ultrasound imaging are used for screening.

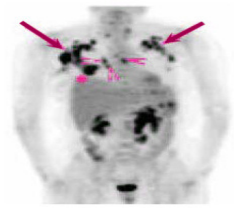

Fig. 4 PET scan Showing Abnormal Lymph Nodes

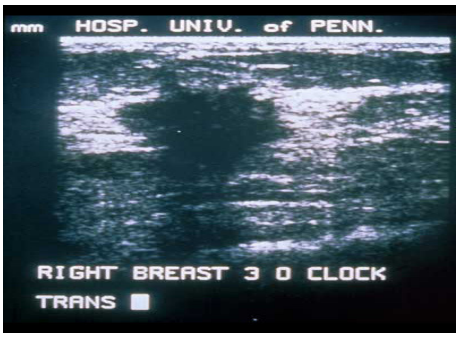

Fig. 5 Ultrasound image showing dark irregular mass [24]

3. Mammography Analysis Techniques

Mammographic images are processed with the help of Image Processing system. Image processing is a physical process used to convert an image signal, either digital or analog, into a physical image. In imaging science, image processing is any form of signal processing for which an image as a input, such as a photograph or video and the output of image processing may be either an image or a set of characteristics or parameters related to the image. For processing mammographic images we will use different stages of image processing to obtain results. The three general phases that all types of data have to undergo while using digital technique are Pre- processing, enhancement, segmentation and classification.

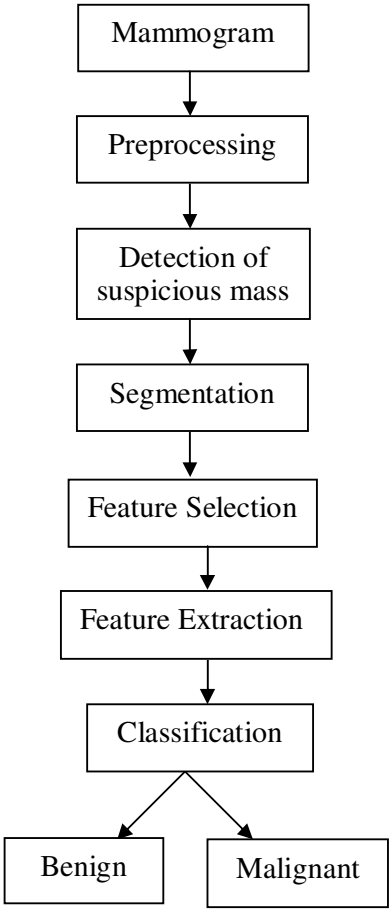

Fig. 6 Block diagram of Mammogram Analysis and Mass Detection scheme

A. Pre-processing of Mammograms

This is the step taken before the "major" image processing task. It may involve the removing of noise, enhancing the contrast, identifying regions likely to contain

(a) The original image
(b) After removing noise

Fig.7 Removing Noise from an Image [31].
the Postcode.

Pre-processing methods use a small neighborhood of a pixel in an input image to get the output image with a new brightness value. Such pre-processing operations are also called filtration.

According to the goal of the processing, pre-processing methods can be divided into the two groups:

1) Image smoothing suppresses noise or other small fluctuations in the image.
2) Gradient operators are based on local derivatives of the image function. Local derivatives are bigger at locations of the image where the image function undergoes rapid changes. Gradient operators aim is to indicate such locations in the image.

B. Image Segmentation

Image segmentation is the division of an image into meaningful structures, is often an essential step in analysis of image, visualization, representation of object and many other image processing tasks. It focuses on methods that find the particular pixels that make up an object. A great variety of segmentation methods has been proposed in the past decades, and some categorization is necessary to present the methods properly here. A disjunct categorization does not seem to be possible though, because even two very different segmentation approaches may share properties that defy singular categorization. Here categorization presented is regarding the *emphasis* of an approach than a strict division.

The following categories are used:

a) Threshold based segmentation
Histogram thresholding and slicing techniques are used for the image segmentation. They may be applied directly to an image, also it can be combined with pre- and post-processing techniques.

b) Edge based segmentation
In this technique, detected edges in an image are used to identify these objects and assumed to represent object boundaries.

c) Region based segmentation
A region based technique starting is done in
the middle of an object and then "growing" outward until it meets the object boundaries.

d) Clustering techniques
Here, clustering methods attempt to group together patterns that are some sort of similar.

e) Matching
When we wish, what an object to identify in an image some what looks like, this knowledge we can use to locate the object in an image and this approach to segmentation is called matching.



Fig. Example of segmentation by thresholding

C. Feature Extraction

Feature extraction is determining various attributes as well as properties associated with a region or object. Feature extraction is a data reduction by measuring certain features or properties that distinguish objects or their parts. During this process, only the salient features necessary for the recognition are retained. As a result, classification methodologies can be implemented in a space with vastly educed dimension and, consequently, need reasonable time. In [5], Cheng et al. have summarized the different primitives used in the characterization of masses detected in mammographic images. These characteristics are:

1) Primitives related to the detected masses: It is directly extracted from the mammogram: the area, compactness, perimeter, elongation, direction, eccentricity, thickness, line, background, foreground, orientation, distance and contrast [11, 26, 27].

2) Co-occurrence matrix: Energy, contrast, entropy are primitives extracted from the matrix of gray levels dependence [28].

3) Surround region dependence matrix: Every ROI is studied comparing to its surrounding neighbours [29].

4) Gray level run length: The statistical primitives used to characterize the mammograms texture are extracted from the matrix GLRL [30].

5) Gray level difference: Primitives are extracted from the matrix GLD that characterize the variance of gray level between the ROI [30].

6) Wavelet decomposition: Many primitives characterizing gray-levels frequencies from different orientations provided by wavelets [8].

7) Gabor filter bank: Primitives extracted from the Gabor filter bank which characterizes the gray-levels frequencies [8, 11, 14].

8) Space scale: *I*t considers spatial primitives. The most common is the Gaussian Laplacian filter.

9) Characteristics of clusters: It shows description of the weight distribution, the area and the number of microcalcifications [16, 17, 26].

The use of primitives related to detected masses can offer almost perfect results. The characterizing techniques should not be evaluated separately, but rather in association with the classification approach.
`

D. Classification

In any effort at designing a classifier it is essential to have a training set of images. Either the classes to which the images belong are known (supervised learning) or they are unknown (unsupervised learning), in which case the most appropriate classes must be found.

The process of using data to determine the best set of features for a classifier is known as training the classifier. The most effective methods for training classifiers involve learning from examples. A performance metric for a set of features, based on the classification errors it produces, should be calculated in order to evaluate the usefulness of the features. Learning refers to some form of algorithm for reducing the classification error on a set of training data [2].

For he classification several types of classifier are used to distinguish malignant from benign masses in mammographic images [5, 6], some most commonly used are Neural networks [7, 8, 9, 10], K nearest neighbours [11, 12, 13], Bayesian classifier [10, 14], Quadratic classifier [15], Linear classifier [16],Expert system [17], Fuzzy decision tree [18], Binary decision tree [19], Genetic algorithms [20], SVM [21, 22] and Adaptive thresholding [23] Cheng et al. have evaluated the accuracy of the different classifiers for malignancy analysis as follows: from 87% to 90% for neural networks classifiers, from 71.08% to 83.13% for the k-nearest neighbours technique, from 94% to 97.3% with decision tree [5]. This accuracy is highly sensitive to the primitives' selection during the characterization step.

4. Conclusion

In the entire screening process, patient's risk profile can be providing a better guideline for detecting early stage breast cancer. Still mammography plays a major role in breast cancer screening. CT/PET scans are useful for detecting spread of breast cancer in other parts of body. MRI is recommended for women with higher risk of developing breast cancer and monitoring for recurrence. Ultrasound is a valuable tool used to complement other screening tests. While combination of mammography, ultrasound, and MRI can provide better results. Their combined use increases the performance of detecting breast cancer and also reduces the rates of false detections.

Over the last decade, breast analysis techniques have been improved rapidly. However, there are still issues to be solved: developing better and new techniques of pre-processing feature extraction, segmentation and classification (using advanced texture analysis for example). There is a need for selecting better criteria for performance evaluation.

References

[1] http://www.cancer.org

[2] Geoff Dougherty, "Digital Image Processing for Medical Applications", First Edition.

[3] D. L. Monticciolo,"Magnetic Resonance Imaging of the Breast for Cancer Diagnosis and Staging." Seminars in Ultrasound CT and MRI, Vol 32, no.4,pp.319-330,2011.

[4] Md. Shafiul Islam, Naima Kaabouch, and Wen Chen Hu, "A Survey of Medical Imaging Techniques Used For Breast Cancer Detection" 978-1- 4673-5208-6/13/2013 IEEE.

[5] H.D. Cheng, X. Cai, X. Chen, L. Hu, X. Lou, "Computer-aided detection and classification of microcalcifications in mammograms: a survey", Pattern Recognition 36-2003, 2003, pp 2967 – 2991.

[6] A. Oliver, J. Freixenet, R. Marti, R. Zwiggelaar, A comparison of breast Tissue classification Techniques, MICCAI 2006, LNCS 4191, pp. 872- 879, 2006.

[7] C.H. Chen, G.G. Lee," Image Segmentation using multiresolution Wavelet analysis and expectation-maximization (EM) algorithm for digital mammography, J. Digital Imag. 8, 1997, pp 491–504.

[8] J. Dheeba, G. Wiselin Jiji, Detection of Microcalcification Clusters in Mammograms using Neural Network, International Journal of Advanced Science and Technology, Vol. 19, Jun 2010.

[9] J.S. Jasmine, A. Govardhan, S. Baskaran, Classification of Microcalcification In Mammograms using Nonsubsampled Contourlet Transform and Neural Network, European Journal of Scientific Research, ISSN 1450-216X Vol.46 No.4 (2010), pp.531-539, 2010

[10] K. Kavitha, N. Kumaravel, A comparative Study of Various MicroCalcification Cluster Detection Methods in Digitized Mammograms, Systems, Signals and Image Processing, pp 405-409, 2007

[11] T. Bhangale., U.B. Desai., U. Sharma.,"An unsupervised scheme for detection of microcalcifications on mammograms", IEEE International Conference on Image Processing, September 10–13, 2000, pp. 184–187.

[12] N. Karssemeijer, Automated classification of parenchymal patterns in mammograms, Phys. Med. Biol. 43, pp. 365–378, 1998.

[13] D. Kramer, F. Aghdasi, Texture analysis techniques for the classi"cation of microcalcifications in digitized mammograms, Proceedings of the 1999 Fifth IEEE AFRICON Conference Electrotechnical Service for Africa, September 28–October 1, 1999, pp. 395–400, 1999

[14] R. Nakayama, Y. Uchiyama, K. Namba, CAD Scheme using Filter Bank for Detection of MCC in

Mammograms, IEEE Transactions on Bio Medical Engineering, vol.53, No.2, pp. 273-283, 2006.

[15] J. Marti, J. Batle, X. Cufi, J. Espanol, Microcalcification evaluation in Computer assisted diagnosis for digital mammography, Proceedings of the 1999 EE Colloquium on Digital Mammography, 1999, pp. 1–6, 1999

[16] J. S. DaPonte, P. Sherman, Classification of ultrasonic image texture by statistical discriminant analysis and neural networks, Comput. Med. Imag. Graphics 15 (1) (1991) 3–9, 1991

[17] L.P. Cordella, F. Tortorella, M. Vento, Combing experts with different features for classifying clustered microcalcifications in mammograms, Proceedings of 15th International Conference on Patten Recognition, 2000, pp. 324–327, 2000

[18] S. Bothorel, B.B. Meunier.,S. Muller, "A fuzzy logic based approach for semiological analysis of microcalcifications in mammographic images", Int. J. Intelligent Systems 12, 1997, 819–848.

[19] K.S. Woods, K.W. Bowyer, Computer detection of stellate lesions, International Workshop on Digital Mammography, pp. 221–229, 1994.

[20] C. Castella, "Breast texture synthesis and estimation of the role of the anatomy and tumor shape in the aadiological detection process: from digital mammography to breast tomosynthesis", phd thesis – Ecole Polytechnique Fédérale de Lausanne, thèse no 4347-2009, 20 mars 2009

[21] F. Eddaoudi, F. Regragui, A. Mahmoudi, N. Lamouri, Masses Detection Using SVM Classifier Based on Textures Analysis, Applied Mathematical Sciences, Vol. 5, no. 8, 367 - 379, 2011

[22] L. Nanni, S. Brahnam, A. Lumini, Combining different local binary pattern variants to boost performance, Expert Systems with Applications 38 (2011) 6209–6216, 2011

[23] S. Sharma, A. Oberoi, A new approach for Classification and Detection of Suspicious Lesions in Mammograms based on Adaptive Thresholding, International Conference on Advanced Computing, Communication and Networks'11, pp 427-431, 2011

[24] http://www.breastcancer.org

[25] Boulehmi Hela, Mahersia Hela, Hamrouni Kamel, Boussetta Sana, Mnif Najla, "Breast Cancer Detection: A Review On Mammograms Analysis Techniques", 978-1-4673-6457-7/13/2013 IEEE

[26] D.H. Davies, D.R. Dance, Automatic computer detection of clustered calcifications in digital mammograms, Phys. Med. Biol. 35 (1990) 1111–1118, 1990

[27] K. Marias, S. Petroudi, R. English, R. Adams, M. Brady, Subjective and computer-based characterisation of mammographic patterns, International workshop on digital mammography , pp 552-557, 2002

[28] F. Eddaoudi, F. Regragui, A. Mahmoudi, N. Lamouri, Masses Detection Using SVM Classifier Based on Textures Analysis, Applied Mathematical Sciences, Vol. 5, no. 8, 367 - 379, 2011

[29] C.S. Lee, J.K. Kim, H.W. Park, Computer-aided diagnostic system for breast cancer by detecting microcalcification, SPIE 3335 (1998) 615–626, 1999

[30] J.K. Kim, H.W. Park, Statistical textural features for detection of microcalcifications in digitized mammograms, IEEE Trans. Med. Imag. 18 (3) (1999) 231–238, 1999

[31] Alasdair McAndrew, "An Introduction to Digital Image Processing with Matlab".

[32] W. Yang, and P. J. Dempsey,"Diagnostic breast ultrasound: current status and future directions," Radiologic Clinics Journal, Vol. 45, no. 5, pp. 845-861, 2005.

[33] MIAS database, http://peipa.essex.ac.uk/ipa/pix/mias

Biography

Author A

Prachi Damodhar Shahare has completed Bachelor of Engineering in Information Technology in 2008 from Nagpur University and currently pursuing her Master of Technology in Computer Science and Engineering from Raipur Institute of Technology, Raipur under the supervision of Ram Nivas Giri, Raipur Institute of Technology, Raipur.

Author B

Ram Nivas Giri is presently working as an Associate Professor in Department of Computer Science and Engineering, Raipur Institute of Technology, Raipur. His area of interest is Artificial Intelligence and Artificial Neural Network. He has guided number of M. Tech and B. Tech projects. He has number of research publications at International/National Journals and Conferences.